Rotator Cuff Repair

Indications, Patient Selection, Outcomes

James C. Vailas, M.D.
New Hampshire Orthopaedic Center
September 14, 2013
New Hampshire Musculoskeletal Institute
20th Annual Symposium

Evolution of Arthroscopic Repair

Lanny Johnson, M.D., 1985, staple repair

Eugene Wolf, M.D., 1990, suture repair with metal anchor (Mitek GII)

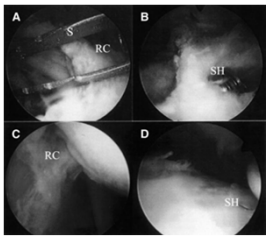

Evolution of Arthroscopic Repair

Similar to capsulorraphy
- Diagnostic convert to open
- Treating other pathologies
- Learning curve
- Continuous improvement techniques
- Continuous improvement in outcomes
- Decreased morbidity
- Outpatient
- Rehabilitation

TRENDS OF REPAIRS

- 141% increase 1996-2006
  - Arthroscopic increased 600% open 34%
  - Repairs done ASCs quadrupled
    Colvin et al, JBJS Am, Feb. 2012
- Acromioplasties decreased 10% 2004-09
  - *Mauro et al, JBJS Am, Aug. 2012*

Rotator Cuff Repair

- Anatomy
  - Gross and Arthroscopic
- Pathological anatomy
- Surgical Indications for Repair
  - Patient Selection
- Arthroscopy Set-up
- Surgical Procedures / Techniques
- Rehabilitation
- Clinical Outcomes

Shoulder Girdle

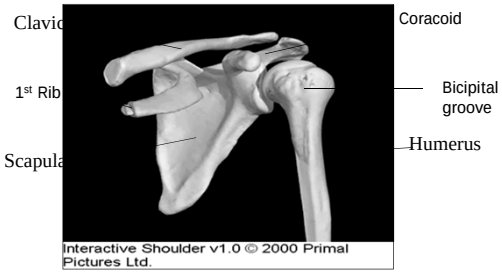

Glenohumeral Joint

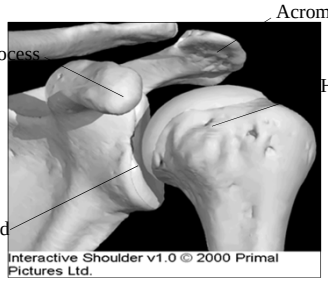

Rotator Cuff

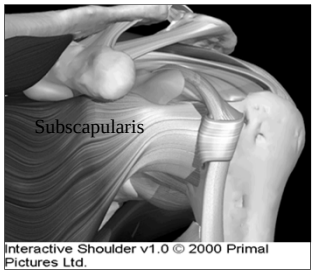

Anterior View

Rotator Cuff

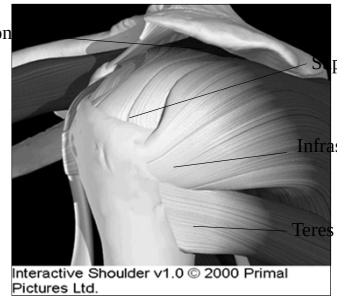

Outlet View

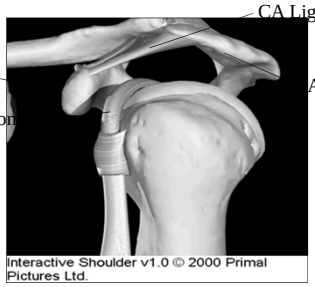

Rotator Cuff

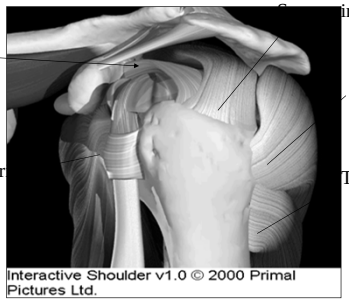

Lateral View

Acromion

<u>Classification</u>

Bigliani

I. Flat
II. Curved
III. Hooked

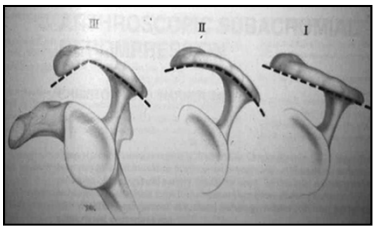

MRI ANATOMY

Rotator Cuff Tear

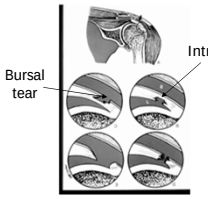

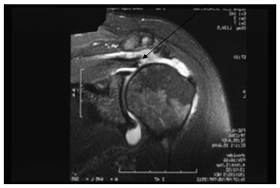

Intra-articular Biceps

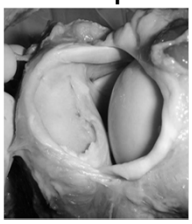

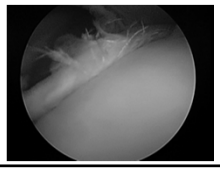

Rotator Cuff Tear

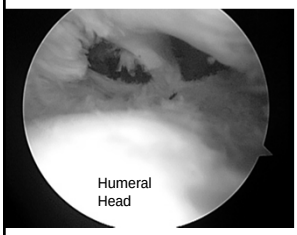

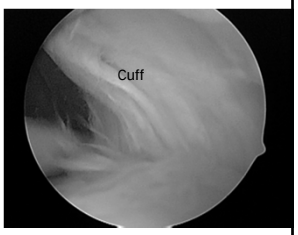

Associated Diagnoses & Pathology

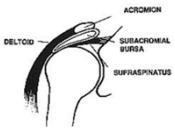

- Impingement: Bursitis;
- Biceps: Tendonitis, tears, SLAP
- Acromioclavicular arthritis
- Instability

Surgical Indications
Patient Selection

- Symptoms - History
  - True shoulder pain
    - Lateral acromial and arm, not forearm
  - Duration >3mos.
  - night pain
  - functional disability with ADLs
  - Failed rehab

Surgical Indications
Patient Selection

- Physical Exam
  - Painful active ROM impingement
  - Cuff weakness
    - Comparative
    - Drop-arm-supraspinatus
    - Horn Blowers-infraspinatus
    - Belly press test-subscapularis
    - Lift-off test

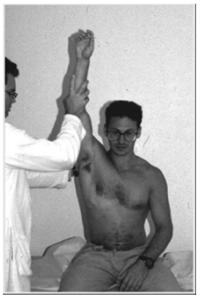

Surgical Indications
Patient Selection

- MRI
  - Complete tears
- MRI arthrogram
  - Partial tears: >50%

Surgical Relative Contra-indications

- Age: >65y.o.
- Fatty atrophy of muscle (Goutallier 4)
- Arthritis
- Large tears, high demands
- Massive tears (2 tendons retracted)
- Adhesive capsulitis

Arthroscopy Setup

Lateral Decubitus

Arthroscopy Setup
Sitting- Captain's Chair



Surgical Procedures

- Decompression
- SLAP Repair
- Rotator Cuff Repair
- Distal clavulectomy
- Biceps tenodesis/ tenotomy

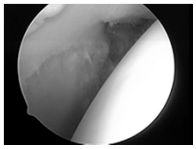

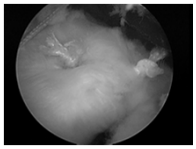

Decompression

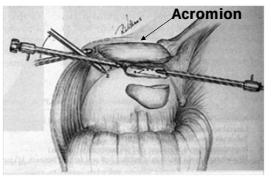

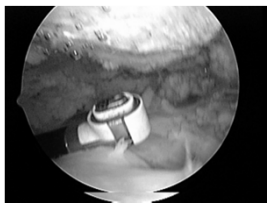

Rotator Cuff Repair

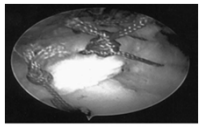

Preop Preparation

-Inflammation & pain
- Pre-emptive meds
  - COX2 NSAID 48hrs
  - Acetaminophen: 1grm.

– Motion: balance flexibility
– Patient education & expectations
- Immobilization
- ADL's
- Return to work/sport
- Long-term symptoms & function

Surgical Technique

Cuff Preparation
- Portal Position
- Bursectomy-visualization
- Tear Pattern-crescent, laminated, L, partial
- Tendon Debridement
- Mobilization / Releases

Surgical Technique

- Trans-tendon
- Single row anchors
- Double row anchors
  - Crossbridging
- Augments Massive tears
- Platelet Rich Plasma

Rehabilitation

- Debate
  - Early Passive motion necessary?
    - Kim et al, Level I PRC study, 105 pts no motion vs passive first four wks

      -ASES, SST, cuff integrity- no difference

      ……is likely safe, it is also not inherently necessary

      AJSM 2012 April

Rehabilitation

- Debate
  Early aggressive vs. limited passive motion
  – Lee et al, Level II RC, 64 pts
  motion increased 3mos.; same 1 yr
  trend for increase tears

Arthroscopy 2012 Jan

Rehabilitation

- Immobilizer
- Passive motion-
  – 7-10 days
- Active assisted 6-8 wks
- Resistance exercise 3 months
- Strenuous exercise 5-6 months
- Full "normal" 9-15mos.

Open repairs Outcomes

- Coefield JBJS 1985
  – 87% pain relief
  – 77% pt. Satisfaction
- Baker & Liu,AJSM 1995
  – 80% good –excellent
  – 88% pt. satisfaction
- Overall results: 71-92%
  – Improved pain, function, strength
- ➢ Smaller tears had better healing and functional outcome
  Gazielly et al CORR 1994

Open repairs Outcomes

Residual defects: 34-90%
Eugene Wolf, Arthroscopy, 2004

20% with SS tendon repair
57% with 2 tendon repairs
66% with 3 tendon repairs
Harryman et al JBJS 1991

41% with 2 tendon repairs
Gazielly et al CORR 1994

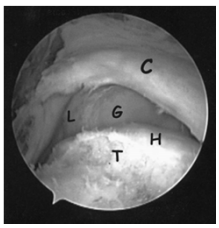

Comparison Mini-open vs. All-Arthroscopic

- Weber et al, 2004 AOSSM
  – 154pts. mini-open & 126 All-arthro
    • Large tears excluded
  – min. f/u 6yrs.
  – ASES, UCLA, SST scores equivalent
  – Retear rates similar
  ➢ ***All-arthro significant reduction peri-operative morbidity***

All Arthroscpic Repair
Massive Tears

- Galatz & Yamagucchi, JBJS '04
  – 18pts. 2 or more tendon tears
  – Ave.age 61
  – min. f/u 2yrs; ave 36mos.
  – ASES scores: Pre-op 48.3 – Post-op 79.9
  – U/S evaluation: **17/18 retears**
  – **All pts. satisfied**
  Possible causes for retears: 1 anchor/1 suture technique; immediate active pulley exercise

All Arthroscopic Repairs

- >90% Satisfaction long term 10yrs
  - 6-8% continued pain and/or weakness

  Intrinsic factors: A-C jt, G-H jt OA; labrum, biceps, deltoid, impingement, adhesive capsulitis, instability

  Extrinsic factors: cervical spine, suprascapular nerve

Millet PJ et al, JSES 2011

All Arthroscopic Repairs

- Literature review 6-24mos f/u
  - 60-90% healed by imaging
  - Significant difference in strength/function healed vs. un-healed

Not all repairs that fail to heal are symptomatic

Slabaugh et al, Arthroscopy 2010

Outcomes Summary All repair techniques

- Patient satisfaction high
- Pain relief high
- Despite structural failures, outcomes better
- Larger the tear the poorer outcome
- Better cuff integrity, better functional outcome

Current Challenges

- Younger, active pt. with large tear
- Better tendon healing
- Modifying rehabilitation appropriate for biology of healing
- Decrease cost of instruments and anchors
- Establish easier techniques

All Arthroscopic Advantage

- Visualizing and magnifying cuff tear
- Multiple angles to tear
- Treating associated pathology
- Short term recovery
  - Pain and ROM
- Large tears
  - Avoiding deltoid morbidity
  - Better mobilization
- Historical progression of orthopaedic surgery

All-arthroscopic Rotator Cuff Repairs

Surgeon Specific Technique

Poorly done arthroscopic repair is worse than a well-done mini-open repair.

Thank You!